

First paediatric case of autochthonous tick-borne encephalitis in the Netherlands, 2018

F. Geeraedts¹, E. van der Kroft² and J. Reimerink³

1) Laboratory for Medical Microbiology and Public Health, Hengelo, the Netherlands, 2) Department of Paediatrics, Ziekenhuis Groep Twente, Almelo/Hengelo, the Netherlands and 3) Centre for Infectious Disease Control, National Institute for Public Health and the Environment, Bilthoven, the Netherlands

Abstract

Since 2016, sporadic cases of autochthonous tick-borne encephalitis (TBE) have been encountered in the Netherlands, in two distinct geographic regions. We describe the first paediatric autochthonous case of TBE, in 2018, which was contracted outside these regions, suggesting that TBE is more widespread. Countrywide vigilance for new TBE cases remains necessary.

© 2019 The Author(s). Published by Elsevier Ltd.

Keywords: Emerging infectious disease, tick-borne disease, tick-borne encephalitis, zoonotic infections

Original Submission: 16 July 2019; **Revised Submission:** 11 September 2019; **Accepted:** 11 September 2019

Article published online: 19 September 2019

Corresponding author: F. Geeraedts, Boerhaavelaan 59, 7555 BB Hengelo, Overijssel, the Netherlands.
E-mail: f.geeraedts@labmicta.nl

Tick-borne encephalitis (TBE) is an emerging disease in the Netherlands and may be underdiagnosed as a result of unawareness. After detection of a genetically divergent European TBE virus (TBEV-NL), genus *Flavivirus*, family *Flaviviridae*, in *Ixodes ricinus* ticks in the *Sallandse heuvelrug* National Park in 2016, three human cases of autochthonous transmission have been reported, involving tick bites in either the *Utrechtse Heuvelrug* or *Sallandse heuvelrug* area [1–4]. Classically, after incubation (4–28 days) TBEV infection runs a biphasic course [5]. A first—viraemic—phase with flu-like symptoms (1–8 days) is followed by an asymptomatic phase (1–33 days), preceding the second—neurological—phase. Symptoms vary from mild meningitis to severe encephalitis, with or without myelitis and spinal paralysis [5,6]. Generally, TBE in western Europe is self-limiting with low mortality rates, and without specific treatment options. Long-lasting sequelae occur in about one-third, less frequently in children [6,7].

On 18 July 2018 a 12-year-old boy was hospitalized with persisting complaints of fever, severe headache, muscle aches,

lack of energy, nausea and diarrhoea, starting on 3 July, when his parents also noticed a lesion on his leg resembling an arthropod bite. Neither physical examination nor a brain MRI showed abnormalities. Serology for Lyme borreliosis and TBE was requested, and while clinically improving, the patient was discharged on 20 July to await the test results. He returned on 21 July because his parents noticed a left-sided facial paresis and he had difficulty controlling movement of his left leg. Cerebrospinal fluid (CSF) revealed leucocytosis ($289 \times 10^6/L$; 95% mononuclear cells). Differential diagnosis included viral meningitis and neuroborreliosis. Treatment with ceftriaxone was started. In the next 4 days the boy's condition deteriorated, showing a left-sided paresis, with a mild Babinski reflex, and left-sided hemianopsia and facial paralysis with decreased sensibility. Lyme serology and PCR on CSF for varicella zoster virus, herpes simplex virus, adenovirus, enterovirus and human parechovirus were negative. A brain MRI following a seizure on 24 July showed hyper-intense lesions suspect for encephalitis and the patient was transferred to an academic hospital. On 27 July serology was positive for anti-TBEV IgM and IgG (Test Line Clinical Diagnostics, Brno, Czech Republic). A virus neutralization test to exclude false-positive results due to cross-reactive antibodies against other flaviviruses confirmed antibody specificity for TBEV [8]. Anti-TBEV IgM and IgG were also

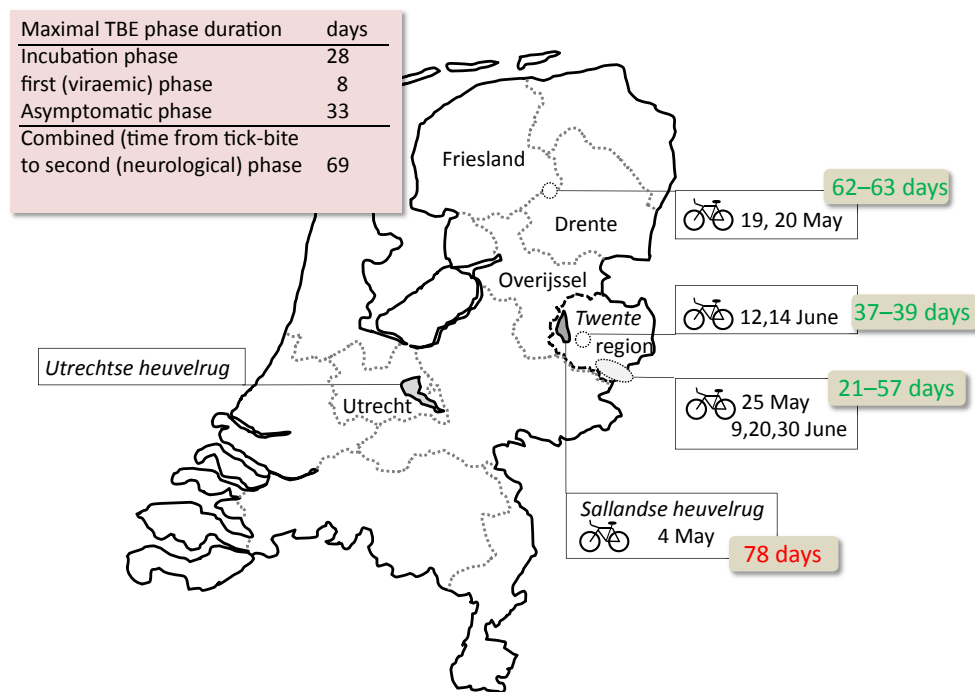


FIG. 1. Geographic locations in the Netherlands of the mountain bike tracks and dates in 2018 of cycling by the patient before he developed tick-borne encephalitis (TBE). The southernmost track in Twente includes a small loop into Germany (1.7 km; total route 60 km). Insert: calculation of the maximal presumptive time interval from tick-bite to neurological symptoms. Given in green and red are the number of days until the presentation of neurological symptoms on 21 July. *Utrechtse heuvelrug* (in the province of Utrecht) and *Sallandse heuvelrug* (in the province of Overijssel) are regions associated with TBE cases in recent years (see also the text).

detected in the CSF, further confirming a definitive case of TBE according to the EU definition [9].

The exact geographic location of the tick bite that transmitted the TBEV remains unknown. There was no history of recent travel or consumption of unpasteurized dairy products, nor had he been vaccinated against any specific flavivirus. According to his parents, tick bites were most frequently noticed after mountain biking. His last cycle session on the *Sallandse heuvelrug*, 78 days before onset of neurological symptoms, seems too far back in time to be related to his illness (Fig. 1). Very likely the infection occurred outside the *Sallandse heuvelrug*, possibly in or near Twente region during one of the most recent cycle sessions before symptoms occurred, indicating that TBE is more widespread than anticipated.

Conflict of interest

The authors have nothing to disclose.

Funding

This research did not receive any specific grant from funding agencies in the public, commercial, or not-for-profit sectors.

References

- [1] Jahfari S, de Vries A, Rijks JM, Van Gucht S, Vennema H, Sprong H, et al. Tick-borne encephalitis virus in ticks and roe deer, the Netherlands. *Emerg Infect Dis* 2017;23:1028–30.
- [2] de Graaf JA, Reimerink JH, Voorn GP, Bij de Vaate EA, de Vries A, Rockx B, et al. First human case of tick-borne encephalitis virus infection acquired in the Netherlands, July 2016. *Euro Surveill* 2016;21(33).
- [3] Weststrate AC, Knapen D, Laverman GD, Schot B, Prick JJ, Spit SA, et al. Increasing evidence of tick-borne encephalitis (TBE) virus transmission, the Netherlands, June 2016. *Euro Surveill* 2017;22(11). pii: 30482.
- [4] Dekker M, Laverman GD, de Vries A, Reimerink J, Geeraedts F. Emergence of tick-borne encephalitis (TBE) in the Netherlands. *Ticks Tick Borne Dis* 2019;10:176–9.
- [5] Haglund M, Gunther G. Tick-borne encephalitis: pathogenesis, clinical course and long-term follow-up. *Vaccine* 2003;21(Suppl. 1):S11–8.

- [6] Lindquist L, Vapalahti O. Tick-borne encephalitis. *Lancet* 2008;371(9627):1861–71.
- [7] Steffen R. Tick-borne encephalitis (TBE) in children in Europe: epidemiology, clinical outcome and comparison of vaccination recommendations. *Ticks Tick Borne Dis* 2019;10:100–10.
- [8] Holzmann H. Diagnosis of tick-borne encephalitis. *Vaccine* 2003;21(Suppl. 1):S36–40.
- [9] European Commission. Commission Implementing Decision of 8 August 2012 amending Decision 2002/253/EC laying down case definitions for reporting communicable diseases to the Community network under Decision No 2119/98/EC of the European Parliament and of the Council (notified under document C(2012) 5538). *Official Journal of the European Union*. Luxembourg: Publications Office of the European Union; 27.9.2012. L 262/34. Available at: <http://eur-lex.europa.eu/legal-content/EN/TXT/PDF/?uri=CELEX:32012D0506&qid=1428573336660&from=EN#page=34>. [Accessed 13 April 2019]. accessed.