

Motorboat Propeller Injuries; A Case Series and Review of the Literature

F. Hoexum,¹ E.A.K. Van Delft,^{1*} G. Van Couwelaar,² A.F.W. Van Der Steeg,³ C.W. Ang,⁴ L.G.M. Geeraedts Jr,¹

F.W. Bloemers,¹ and J. Deunk¹

¹Department of Trauma Surgery, VU University Medical Center, Amsterdam, The Netherlands

²Department of Plastic and Reconstructive Surgery, VU University Medical Center, Amsterdam, The Netherlands

³Department of Pediatric Surgery, VU University Medical Center, Amsterdam, The Netherlands

⁴VU University Medical Center, Department of Medical Microbiology and Infection Control, Amsterdam, The Netherlands

*Corresponding author: E.A.K. Van Delft, Department of Trauma Surgery, VU University Medical Center, De Boelelaan 1117, P.O. Box 7057, 1007 MB Amsterdam, The Netherlands. Tel: +31-204444554, Fax: +31-204444512, E-mail: evandelft@gmail.com

Received 2016 June 26; Revised 2016 October 30; Accepted 2016 November 12.

Abstract

Introduction: Injuries inflicted by motorboat propellers are rare but often result in extensive soft tissue and osseous injuries and can have great impact on the functional outcome of the patient. Treatment is challenging and needs a multidisciplinary approach.

Methods: This study retrospectively analyzed 4 cases and performed a PubMed, Embase, Medline and Cochrane literature search. All articles presenting original patient data were included.

Results: In all four cases, a multidisciplinary approach was used. Mean follow up was 15.8 months (range 6 to 35). All patients had some degree of functional impairment with lower Foot and Ankle Outcome Score (FAOS) concerning sport and recreation, and foot- and ankle-related quality of life. A review of the literature revealed 20 articles with 95 reported cases. The most common injury was to the lower extremities (63 limbs). The injury mechanism was available for 84 cases; 62% was water sport related. In 18 cases, the propeller injury resulted in an amputation of the affected extremity. Twenty fatalities could be identified.

Conclusions: Motorboat propeller injuries can be severe and even fatal. Lower extremities are particularly at risk, resulting in extensive soft tissue and osseous injuries with a significant risk of subsequent amputation. The impact on functional outcome can be significant. A patient-based and multidisciplinary approach is necessary to ensure an optimal outcome.

Keywords: Propeller, Injury, Trauma, Lower Extremity, Fracture, Review

1. Introduction

Trauma is one of the biggest causes of disability in young people and the single greatest cause of years of life lost in the world as well as is the fourth leading cause of death in the world (1). Injuries inflicted by propellers of (outboard) motors are rare but can be severe with the management being often challenging. The recreational use of open water has increased the risk of motorboat related injuries. Circumstances are commonly water sports like waterskiing, however most patients are accidentally run over or thrown from a boat (2). Injuries due to the motorboat propeller are frequently deep, parallel lacerations with extensive damage to soft tissues and osseous structures (3-6). Based on 4 cases and a literature review we outline the management of these challenging injuries.

1.1. Methods

We retrospectively analyzed the data of our patients with propeller injuries treated at our level-1 traumacenter during a 25-month period. Written informed consent was

obtained and all four patients were requested to complete the Dutch translated version of the Foot and ankle outcome score (FAOS) questionnaire at follow up. The FAOS is a self-administered questionnaire intended to evaluate symptoms and functional limitations related to feet and ankles, consisting of 5 subscales; pain, other symptoms, function in daily living, function in sport and recreation and foot and ankle-related quality of life (7). A normalized score is calculated for each subscale (100 indicating no symptoms and 0 indicating extreme symptoms). In addition, as part of this study a review of the English literature based on a PubMed, Embase, Medline and Cochrane search was performed. Keywords used were: outboard, motor, boat, propeller, and injury/injuries. All articles written in English presenting original patient data regarding human subjects were included. Reference lists of included articles were hand searched.

2. Case Presentation

2.1. Patient 1

A 21-year-old male was sitting on a motorboat with his right foot in the water. Because of a sudden thrust, his foot was sucked into the propeller, injuring his lower leg. There was extensive soft tissue injury at the medial side of the ankle and a traumatic amputation of the medial malleolus including the deltoid ligament. Despite extensive damage, there were no signs of neurological injury (Figure 1A). Following initial assessment, he was transferred to the operating theatre immediately. After wound exploration and debridement, both the Achilles and posterior tibial tendon were reconstructed. Subsequently the ankle was stabilized with external fixation and the first metatarsal with an additional K wire. Primary closure of the wound was impossible and therefore the defect was closed by the plastic/reconstructive surgeon with an anterolateral thigh (ALT) flap (Figure 1B). On empirical basis, amoxicillin/clavulanic acid was administered (5 days IV followed by 3 days orally). The postoperative course was uncomplicated. There were no signs of infection and the patient was discharged after nine days. Three weeks after surgery, the external fixation was removed. During his admission, he received clinical physiotherapy to regain mobility; after discharge he was treated by a physiotherapist as an outpatient. Two years after his accident, a tenotomy was performed because of muscle contraction of the flexor digitorum II and III of his right foot. He had persistent complaints during running and climbing stairs but was able to mobilize with adaptive footwear, normally during his daily activities. At 35 months follow-up, his FAOS were as follows, pain 78/100; other symptoms 64/100; function in daily living 68/100; function in sport/recreation 30/100 and foot and ankle-related Quality of Life 38/100.

2.2. Patient 2

A 14-year-old male was struck by a propeller after jumping from a boat. He sustained parallel lacerations of the medial side of the right ankle and an open fracture of the calcaneus (Figure 2A). Radiographs and a computerized tomography (CT)-scan showed a fracture of the calcaneus, fractures of the talus, navicular and several avulsion fractures (Figure 2B). He was admitted for surgery immediately. In the operating theatre, wound exploration was performed by an orthopedic trauma surgeon, pediatric surgeon and plastic surgeon. The posterior tibial artery was transected. However, adequate vascularization of the foot was provided by the anterior tibial artery and peroneal artery. Therefore, no reconstruction of the posterior tibial artery was performed. The bone fragments of the calcaneus and navicular bone were fixated with K-wires (Fig-

ure 2C). The soft-tissues were primarily closed after extensive lavage and finally an external fixation was used to obtain additional stability. Prophylactic antibiotic treatment with cefuroxime at presentation to the emergency department and a repeated dose during operation was administered. After consultation of the microbiologist, tobramycin and piperacillin for six days was given on an empirical basis. The postoperative course was uncomplicated. He was discharged after seven days. During his admission, he received clinical physiotherapy to regain mobility. After six weeks, the K-wires and external fixator were removed. During his further recovery, he was treated by a physiotherapist as an outpatient. At 10 months follow-up, he had no problems during his daily activities and was able to play soccer. His FAOS were as follows, symptoms 86/100; pain 96/100; function in daily living 100/100; function in sport/recreation 85/100 and foot and ankle-related quality of life 75/100.

2.3. Patient 3

A 48-year-old male tried to climb into the small vessel while his friend started the outboard motor. His foot was swept into the propeller causing lacerations on the lateral side of his foot with open comminuted fractures of the calcaneus, talus, lateral cuneiform, 2nd and 3rd metatarsal bones and of his fifth digit (Figures 3 and 4). On clinical examination there was numbness of the fifth digit and the lateral edge of the foot, suggesting injury to the peripheral branches of the sural nerve. Wound exploration in the operating theatre, directly after the trauma, showed an avulsion fracture of the attachment of the Achilles tendon to the calcaneus and injury to the peroneal tendon. After K-wire fixation of the calcaneus and the fifth digit, the peroneal tendon was reconstructed (Figure 3B). The injury to the peripheral branches of the sural nerve were treated conservatively. Despite extensive soft tissue injury of the foot, primary closure of the wound was possible. Three doses of peri-operative cefuroxime IV were administered. After consulting the microbiologist, the patient was treated for five days with piperacillin and tobramycin. After five days, antibiotics were switched to an oral regimen; ciprofloxacin and clindamycin for another five days. After five days he was discharged. Clinical physiotherapy was given during his admission and was continued as an outpatient. Eight weeks after the initial trauma, the K wires were removed. Nevertheless, the injury continued to have a major impact on his daily well-being. At six months follow up his FAOS were as follows, symptoms 78/100; pain 71/100; function in daily living 90/100; function in sport/recreation 45/100 and foot and ankle-related quality of life 25/100.

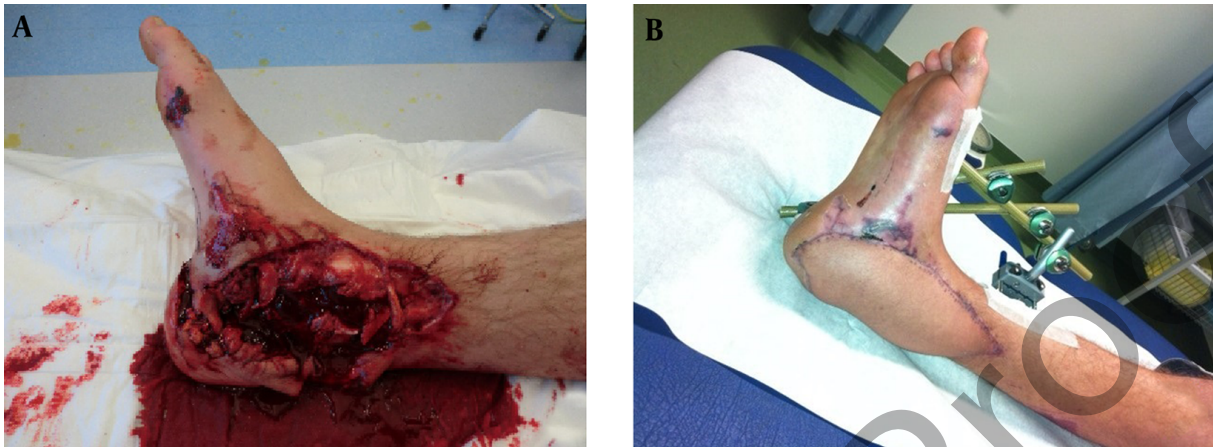


Figure 1. Case 1. A, trauma photo: extensive injuries to medial side of the ankle; B, reconstruction with an ALT flap, external fixator in situ.

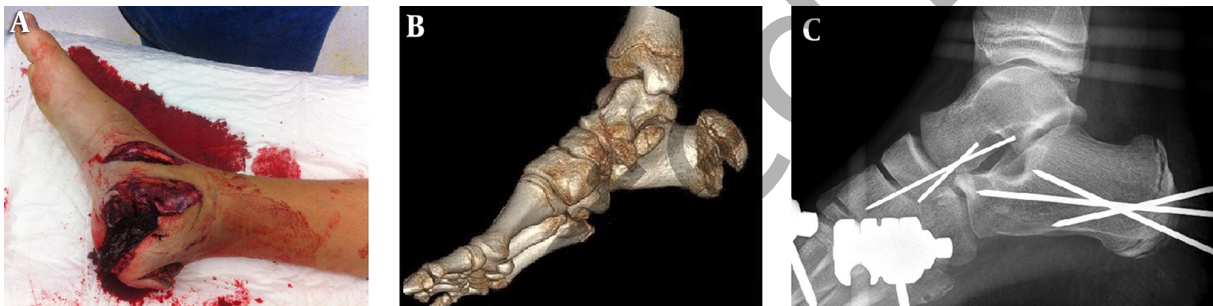

Figure 2. Case 2. A, Trauma photo: Extensive injuries to medial side of the ankle; B, 3D computed tomography reconstruction: fractures of the calcaneus, talar and navicular bone; C preoperative fluoroscopy: internal fixation with 3 K-wires.

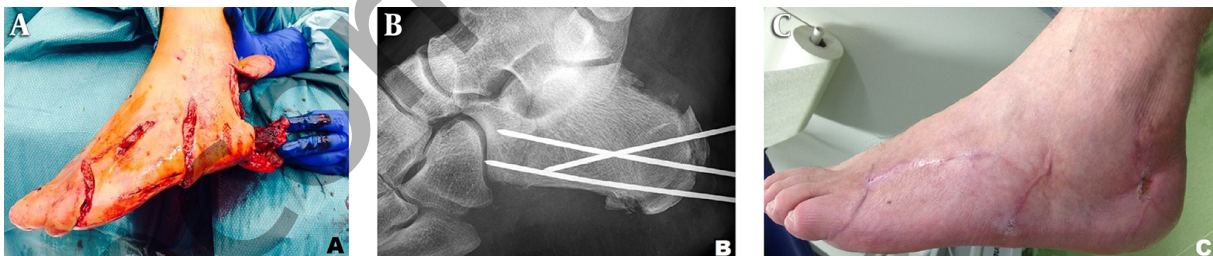


Figure 3. Case 3. A, left foot: Typical lacerations; B, preoperative fluoroscopy: internal fixation with 3 K-wires; C Photo at 6 months follow up: Almost completely healed wounds.

2.4. Patient 4

A 10-year-old girl fell off a motorboat and her left leg got struck by the propeller, causing extensive injury to her leg and ankle. She received a prophylactic dose of cefazolin IV during transportation to our emergency department. At presentation, there was a subtotal traumatic amputation through the distal tibia with deep semicircular lacerations (Figure 4). Physical examination showed loss

of sensibility but still an adequate capillary refill of the left forefoot and toes. She was admitted to the operation room immediately. During an eleven-hour operation, a specialized team of (orthopedic) trauma, pediatric and plastic surgeons performed a reconstruction of the lower extremity. After exploration and extensive debridement, the distal tibia and fibula were stabilized with K-wires and one lag screw. Next, revascularization of the lacerated posterior

tibial artery was performed using a venous graft from the great saphenous vein. Subsequent reconstruction of the tibial nerve (3 cm) was performed using the sural nerve and the lateral femoral cutaneous nerve. The posterior tibial musculature was approximated and the soft tissue deficit was reconstructed using an anterolateral thigh (ALT) flap connected to the anterior tibial artery and vein. Finally, an external fixator was placed for additional stabilization of the osseous injuries and soft tissues. During the operation, she received a prophylactic dose of cefazolin and tobramycin IV. Adequate postoperative analgesic therapy was provided by an epidural (PCEA). Because of partial necrosis of the ALT-flap, a debridement of the foot was performed twelve days after the initial operation and a persistent defect was reconstructed using a gracilis flap. In consultation with a pediatric dietician, a nasogastric tube was placed for tube feeding because of insufficient oral intake. During the period of admission, the patient was treated by a physiotherapist. After six weeks, the external fixation could be removed, after which a wound infection occurred. Wound cultures showed *S. aureus* and *Aeromonas hydrophila/caviae*, hereupon in consultation with the microbiologist, antibiotic treatment with flucloxacillin and gentamicin IV was started. After two days, the fever had disappeared and we switched to clindamycin orally. Further recovery went uneventful and she was discharged 57 days after the accident to a rehabilitation center. After 12 months, she was able to resume her daily activities with the use of a ToeOFF brace. She was even playing field hockey again as a goalkeeper. Without the brace, her functional impairment increased significantly. Her FAOS with the ToeOFF brace were as follows, symptoms 36/100; pain 100/100; function in daily living 84/100; function in sport/recreation 50/100 and foot and ankle-related quality of life 38/100.

2.5. Review of the Literature

Twenty articles presented original patient data regarding 95 cases with a total of 148 injuries (2-6, 8-22). The level of evidence of all articles was IV. Patient demographics and injury characteristics are shown in Table 1. Most patients were male (71%, n = 65) and mean age was 25 years. Although most injuries were water sport related (62%, 52/95), the most common mechanism of injury was a fall from a boat or accidental running over a person (n = 23). As visualized in Table 2, injury to the lower extremity was most common (63/95). Amputation was reported in 18 patients. Table 2 also shows the reported outcomes in the literature. Outcomes were reported in 66% (63/95). No objective measures were used for grading functional outcomes. Twenty fatalities could be identified. Full recovery was claimed in

21 patients, recovery with deficits was reported in 22 patients. Those deficits were unfortunately not described in detail, so we were unable to compare them with our patients.

Some articles emphasized the indication of a multidisciplinary approach. Despite this, in none of the articles a clear advice of treatment or a guideline was disclosed.

All patients and/or their legal representatives (parents) gave a written consent for publication of the photo's and radiologic images.

3. Discussion

Incidence and epidemiologic data: Injuries due to motorboat propellers are uncommon, but true incidences remain unclear (2, 3, 8, 10). In 2009 - 2013, a total of 915 cases of propeller injuries were reported, with 129 deaths (14.1%) in the United States of America. Of all boating-related injuries, 2.6% was caused by propeller strikes (23). These numbers are probably underestimating the real amount of injuries because not all non-fatal accidents are reported (17, 24). Boating-related injuries are more common during the summer period, with the highest prevalence in people between 11 and 20 years (17, 23).

Trauma mechanism and injury pattern: Propeller injuries are caused by the great impact of the moving blades of the propeller. The lower extremity is particularly at risk for becoming in contact with the blades. The wounds are characteristically parallel repeated, deep and clear-cut lacerations with potential loss of bony structures and soft tissues (3-6). Our literature review shows that of all reported cases, falling and being run over by a boat (n = 23) is the most common injury pattern.

Management: The management of these injuries is in line with the treatment of complex compound fractures and should consist of a multidisciplinary approach with close collaboration between (orthopedic) trauma, pediatric and plastic surgeons, the microbiologist and supportive specialists and consist of the following principles;

Debridement and exploration: Extensive debridement, exploration and wound rinsing in the operating theatre is the first step in the surgical treatment. Debridement of soft tissues in open fractures is recommended to be performed as soon as possible in highly contaminated open fractures, or at least within 12 hours for high-energy open fractures, which are not highly contaminated (25). A recent randomized study showed that irrigation with high volume and low pressure saline is sufficient in open fractures (26). Early amputation of extremities can be indicated in case of 'life before limb situations, or in case of little chance of survival of the affected limb (27).

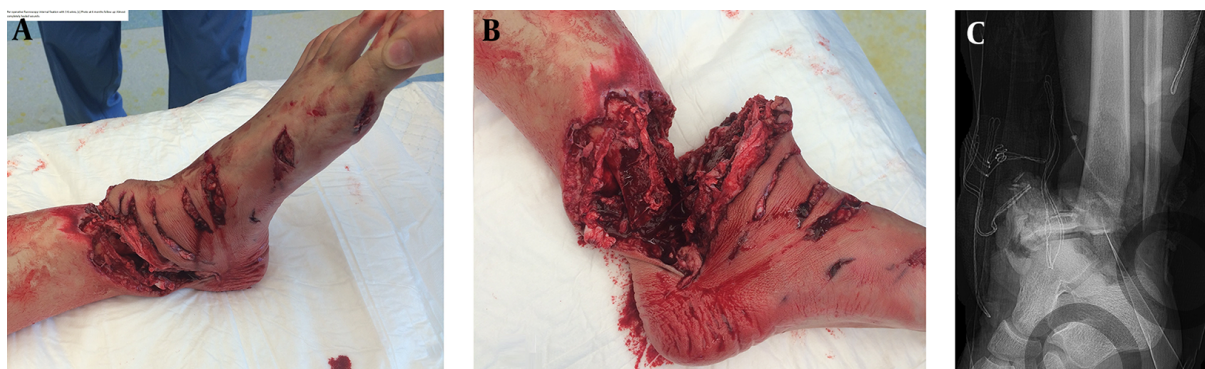


Figure 4. Case 4. A + B, subtotal amputation of the left foot; C, comminuted fractures of the tibia and fibula.

Table 1. Demographics and Trauma Mechanism of Current Literature

Author	N	Gender		Mean Age	Trauma Mechanism			
		M	F		WATERSPORTS			Fall of/Run Over
					Waterskiing	Swimming/Diving	Other	
Mendez-Fernandez 1998 (8)	1	1	0	44	0	1	0	0
Hargarten et al. 1994 (9)	4	1	3	11,3	0	0	1	1
Sladden et al. 2014 (10)	2	2	0	NA	0	0	0	1
CDC 1998 (3)	3	2	1	39	0	0	1	0
Garg et al. 2011 (4)	3	2	1	45	0	2	0	1
Keijzer et al. 2013 (11)	1	1	0	4	0	0	0	1
Semeraro et al. 2005 (12)	1	NA	11	0	0	0	0	
Ihama et al. 2009 (5)	1	1	0	30	0	0	0	1
Di Nunno and Di Nunno 2000 (6)	9	6	3	27,3	0	6	3	0
Mann et al. 1976 (2)	13	9	4	26		4		4
Roos et al. 1994 (7)	17	17	0	18,3	5	4	0	5
Dhall et al. 2008 (13)	1	0	1	26	0	0	0	0
Noonburg et al. 1989 (14)	7	7	0	30,4	2	1	0	4
Klingman et al. 1991 (15)	2	0	2	23	0	0	1	1
Kutarski 1989 (16)	5	4	1	24,6	1	1	2	0
Price and Moorefield 1987 (17)	3	0	3	NA	1	2	0	0
Norouzi et al. 2013 (1)	9	5	4	26,8	4	1	1	2
Hummel and Gainor 1982 (18)	6	5	1	24,3	1	0	0	2
Paterson 1971 (21)	5	1 ^a	2 ^a	NA	1	3	1	0
Jackson 1965 (22)	2	1	1	28	2	0	0	0
Total	95	65	27	25,1 (4 - 61)	17	5221	10	23

Abbreviations: N, number; NA, not available.

^a2Not available.

Reduction and fixation of the osseous injuries: Temporary K-wires and screws can be applied without substantial

additional soft tissue damage. External fixation can be applied for initial management and stabilization of osseous

Table 2. Injuries and Amputations in the Current Literature

Author	N	Injuries						Amputation		Outcome	
		Head	Thorax	Abd.	Pelvis	Upp.extr.	Low.extr.	Traum.	Surg.	Fatalities	Full Recovery
Mendez-Fernandez (8)	1	0	1	0	0	0	0	0	0	-	1
Hargarten et al. (9)	4	0	0	1	1	1	2	0	1	-	1
Sladden et al. (10)	2	2	1	1	0	1	1	0	0	2	-
CDC (3)	3	0	0	0	0	0	4 ^a	0	0	-	1
Garg et al. (4)	3	1	2	2	2	1	2	1	0	3	-
Keijzer et al. (11)	1	1	0	0	0	0	0	0	0	-	-
Semeraro et al. (12)	1	0	0	0	0	0	2 ^a	0	0	-	-
Ihama et al. (5)	1	1	1	0	0	1	0	0	0	1	-
Di Nunno and Di Nunno (6)	9	2	1	1	1	3	12 ^a	0	3	1	4
Maan (2)	13	1	1	0	0	0	0	0	0	3	3
Roos et al. (7)	17	1	0	2	1	4	10	0	1	3	-
Dhall et al. (13)	1	0	0	1	1	0	1	0	1	-	-
Noonburg (14)	7	2	1	1	1	3	4	0	1	1	6
Klingman et al. (15)	2	1	0	0	1	0	3 ^a	0	0	1	1
Kutarski (16)	5	1	0	0	2	0	5	1	0	1	-
Price and Moorefield (17)	3	0	0	0	3	0	3 ^a	1	0	-	2
Norouzi et al. (1)	9	0	3	3	1	2	4 ^a	3 ^a	1	3	1
Hummel and Gainer (18)	6	0	1	0	1	4	7 ^a	0	2	-	1
Paterson (21)	5	0	0	0	0	1	3	2	1	-	-
Jackson (22)	2	2	0	0	0	0	0	0	0	-	-
Total	95	15	12	12	15	21	63	18	20	21	

Abbreviations: Surg, surgical; Traum, traumatic; Up. Extr, upper extremity.

^a Bilateral injuries/amputations are counted as 2.

injuries, to obtain a correct length, axis and rotation of the limb and to protect the soft tissues (4). Ruptured tendons and ligamentous injuries should be addressed after stabilization of the bones and restoration of the length, axis and rotation to prevent the possibility of inadequate reconstruction.

Reconstruction of neurovascular injuries: The lacerations caused by the propeller can lead to injuries of the neurovascular structures with tissue loss. Primary reconstruction of the neurovascular structures is therefore rarely possible and the use of interposition grafts is frequently indicated. In case of critical ischemia due to arterial injuries, arterial reconstruction should be performed within 3 to 4 hours to prevent irreversible damage (28). In case of mild ischemia and serious disruption of length, axis and rotation of the effected extremity, it should be considered to address the osseous injuries first to prevent failure of the revascularization. Temporary arterial shunting can also be considered before stabilization of the bones (29). After stabilization, definitive reconstruction can then be performed. In contrast to vascular injuries, delayed peripheral nerve reconstruction can be successful (30). However, early nerve reconstruction should be considered before definitive soft tissue coverage is performed. The recon-

struction of the tibial nerve is important in the functional outcome, since it supplies the sensibility of the foot sole.

Soft tissue closure and reconstruction: Adequate coverage with soft tissues is essential. If primary closure is not possible, soft tissue reconstruction has to be performed by local transposition or by a free flap reconstruction. Early coverage of the wounds has a lower rate of infection compared to open care of wounds (31). If soft-tissue covering cannot be performed immediately it should preferably be done within 72 hours (25). Delayed treatment of the soft tissue injury and open fractures is associated with a higher rate of infection (31). Several authors report the use of skin grafts and flap reconstructions in the treatment of propeller injuries (2, 4, 8, 15, 19, 20). In case primary closure is considered, postoperative edema and the subsequent increase in pressure to the soft tissues has to be taken into account. Vacuum assisted closure devices have also been used as a temporarily adjunct for wound closure (4).

Infection prevention and antibiotic treatment: Propeller wounds invariably get infested by bacteria from the aquatic environment. Debridement is essential for adequate treatment as it minimizes the breeding ground for bacteria and reduces bacterial load (8). In both freshwater and saltwater, a large variety of bacteria are present. In our

opinion, the empiric antibiotic regimen should be based on the type of aquatic environment (fresh water versus salt or brackish water). In the literature, a wide range of antibiotic regimens is recommended including almost every antibiotic class (4, 9, 15, 16, 19). Early infections associated with freshwater are caused by typical aquatic bacteria such as *Aeromonas* spp., *Pseudomonas* spp., and a variety of other gram-negatives (*Escherichia coli*, *Klebsiella* spp., *Shewanella* spp.) but also by *Staphylococcus aureus* and *Streptococcus pyogenes* (group A). A specific micro-organism, which can be found in freshwater is *Aeromonas hydrophila*. One of our patients had a positive wound culture for this bacteria. This infection mimics a *Staphylococcus* infection, but can rapidly progress to a very painful infection with fever, lymphadenopathy and bullae with purulent discharge with the possibility to progress to necrotizing fasciitis or osteomyelitis. The incubation period for *Aeromonas hydrophila* infection is usually one or two days. The number of bacteria present in water is higher during the summer period (32). Early infections associated with salt water environments are caused by bacteria such as *Vibrio* spp (mainly *V. vulnificus*). In later stages, non-tuberculous mycobacteria such as *Mycobacterium marinum*, *M. abscessus* and *M. fortuitum* may cause infections. Based on the epidemiology of aquatic bacteria and associated infections, we recommend prolonged antibiotic prophylaxis for 5 - 7 days depending on the severity of the trauma and the extent of the soft tissue injury, with a combination of a penicillin with anti-pseudomonal/aeromonas activity (e.g. piperacillin) with an aminoglycoside (e.g. gentamicin or tobramycin) or a third-generation cephalosporin with anti-pseudomonal activity (ceftazidime) or a fluoroquinolone (e.g. ciprofloxacin). Patients with a penicillin allergy should be treated by a third-generation cephalosporin with anti-pseudomonal activity (cefazidime) or a fluoroquinolone (e.g. ciprofloxacin). For salt-water injuries, we recommend use of an aminoglycoside to cover infection caused by *Vibrio* spp. Noonburg also described the presence of *Clostridium tetani* in sea or brackish water and therefore advised to treat patients with a tetanus booster if their last immunization has been more than 10 years ago (14).

Supportive care: The management of motorboat propeller injuries is complex and it needs a multidisciplinary approach, of which case 4 is a good example.

Outcomes: Although all of our patients were able to resume their daily activities (some with adaptive footwear/brace), they all had in greater or lesser extend functional impairment with lower FAOS scores concerning sport and recreation, and foot- and ankle-related quality of life. None of our patients reported signs of complex regional pain syndrome.

Conclusion: Motorboat propeller injuries can result in extensive damage to soft tissue and bones with severe functional disability, amputation and even death as a result. Thorough surgical debridement and irrigation, fixation of osseous structures, reconstruction of neurovascular and soft tissues, prevention and treatment of infection and supportive care are all key elements in the treatment of these injuries. A multidisciplinary approach is essential to ensure an optimal outcome.

Footnotes

Conflict of Interest: The authors declare that they had no conflict of interest.

Financial Disclosure: None.

References

1. Norouzi V, Feizi I, Vatankhah S, Pourshaikhian M. Calculation of the probability of survival for trauma patients based on trauma score and the injury severity score model in fatemi hospital in ardabil. *Arch Trauma Res.* 2013;2(1):30-5. doi: [10.5812/atr.9411](https://doi.org/10.5812/atr.9411). [PubMed: [24396787](https://pubmed.ncbi.nlm.nih.gov/24396787/)].
2. Mann RJ. Propeller injuries. *South Med J.* 1976;69(5):567-9. [PubMed: [818713](https://pubmed.ncbi.nlm.nih.gov/818713/)].
3. From the CDC and Prevention . Boat-propeller-related injuries-Texas, 1997. *JAMA.* 1998;279(23):1858. [PubMed: [9634244](https://pubmed.ncbi.nlm.nih.gov/9634244/)].
4. Garg H, Twerenbold R, Zellweger R. Propeller and jet-ski injuries during Christmas and New Year in Western Australia. *Med J Aust.* 2011;195(11-12):704-5. [PubMed: [22171870](https://pubmed.ncbi.nlm.nih.gov/22171870/)].
5. Ihama Y, Ninomiya K, Noguchi M, Fuke C, Miyazaki T. Fatal propeller injuries: three autopsy case reports. *J Forensic Leg Med.* 2009;16(7):420-3. doi: [10.1016/j.jflm.2009.04.006](https://doi.org/10.1016/j.jflm.2009.04.006). [PubMed: [19733336](https://pubmed.ncbi.nlm.nih.gov/19733336/)].
6. Di Nunno N, Di Nunno C. Motorboat propeller injuries. *J Forensic Sci.* 2000;45(4):917-9. [PubMed: [10914598](https://pubmed.ncbi.nlm.nih.gov/10914598/)].
7. Roos EM, Brandsson S, Karlsson J. Validation of the foot and ankle outcome score for ankle ligament reconstruction. *Foot Ankle Int.* 2001;22(10):788-94. [PubMed: [11642530](https://pubmed.ncbi.nlm.nih.gov/11642530/)].
8. Mendez-Fernandez MA. Motorboat propeller injuries. *Ann Plast Surg.* 1998;41(2):113-8. [PubMed: [9718142](https://pubmed.ncbi.nlm.nih.gov/9718142/)].
9. Hargarten SW, Karlson T, Vernick JS, Aprahamian C. Motorboat propeller injuries in Wisconsin: enumeration and prevention. *J Trauma.* 1994;37(2):187-90. [PubMed: [8064913](https://pubmed.ncbi.nlm.nih.gov/8064913/)].
10. Sladden D, Casha A, Manche A. Chest wall reconstruction following a speedboat propeller injury. *Malta Med J.* 2014;26(02).
11. Keijzer R, Smith GF, Georgeson KE, Muensterer OJ. Watercraft and watersport injuries in children: trauma mechanisms and proposed prevention strategies. *J Pediatr Surg.* 2013;48(8):1757-61. doi: [10.1016/j.jpedsurg.2013.03.055](https://doi.org/10.1016/j.jpedsurg.2013.03.055). [PubMed: [23932618](https://pubmed.ncbi.nlm.nih.gov/23932618/)].
12. Semeraro D, Passalacqua NV, Symes S, Gilson T. Patterns of trauma induced by motorboat and ferry propellers as illustrated by three known cases from Rhode Island. *J Forensic Sci.* 2012;57(6):1625-9. doi: [10.1111/j.1556-4029.2012.02177.x](https://doi.org/10.1111/j.1556-4029.2012.02177.x). [PubMed: [22583137](https://pubmed.ncbi.nlm.nih.gov/22583137/)].
13. Dhall SS, Lin FJ, Tumalian LM, Mapstone TB. Significant neurologic recovery following a catastrophic open head injury from a motorboat propeller: case illustration. *J Trauma.* 2008;65(1):249-50. doi: [10.1097/TA.0b013e3180312c52](https://doi.org/10.1097/TA.0b013e3180312c52). [PubMed: [18580537](https://pubmed.ncbi.nlm.nih.gov/18580537/)].
14. Noonburg GE. Management of extremity trauma and related infections occurring in the aquatic environment. *J Am Acad Orthop Surg.* 2005;13(4):243-53. [PubMed: [16112981](https://pubmed.ncbi.nlm.nih.gov/16112981/)].

15. Klingman RR, Smith P, Stromberg B, Valentine J, Goebel M. Traumatic hemipelvectomy. *Ann Plast Surg.* 1991;**27**(2):156–63. [PubMed: [1952740](#)].
16. Kutarski PW. Outboard motor propeller injuries. *Injury.* 1989;**20**(2):87–91. [PubMed: [2687175](#)].
17. Price CT, Moorefield CW. Motorboat propeller injuries. *J Fla Med Assoc.* 1987;**74**(6):399–401. [PubMed: [3668489](#)].
18. Hummel G, Gainor BJ. Waterskiing-related injuries. *Am J Sports Med.* 1982;**10**(4):215–8. [PubMed: [7125042](#)].
19. Banta JV. Epidemiology of waterskiing injuries. *West J Med.* 1979;**130**(6):493–7. [PubMed: [117637](#)].
20. Slight MW. Speedboat propeller injuries. *Br Med J.* 1974;**2**(5916):427–8. [PubMed: [4835301](#)].
21. Paterson DC. Water-skiing injuries. *Practitioner.* 1971;**206**(235):655–61. [PubMed: [5579783](#)].
22. Jackson FE. High Speed Propeller Injuries of the Brain; Report of Two Cases. *Am J Surg.* 1965;**110**:473–6. [PubMed: [14338011](#)].
23. US Coast Guard Boating Safety Division . Recreational Boating Statistics. ; 2013.
24. Chalmers D, Morrison L. Epidemiology of non-submersion injuries in aquatic sporting and recreational activities. *Sports Med.* 2003;**33**(10):745–70. [PubMed: [12895131](#)].
25. National Institute for Health and Care Excellence (NICE) . Guideline: Fractures (complex): assessment and Management (NG37). ; 2016.
26. Flow Investigators , Bhandari M, Jeray KJ, Petrisor BA, Devereaux PJ, Heels-Ansdell D, et al. A Trial of Wound Irrigation in the Initial Management of Open Fracture Wounds. *N Engl J Med.* 2015;**373**(27):2629–41. doi:[10.1056/NEJMoai508502](#). [PubMed: [26448371](#)].
27. Boffard KD. Manual of Definitive Surgical Trauma Care. CRC Press; 2011.
28. The British Association of Plastic . Guideline: Standards for the Management of Open Fractures of the Lower Limb. United Kingdom: Reconstructive and Aesthetic Surgeons (BAPRAS); 2009.
29. AO Foundation . AO Principles of Fracture Management. Soft Tissue loss: principles of management - Emergency management - Revascularization. ; 2010.
30. Neligan PC. Plastic surgery. Repair and grafting of peripheral nerve. Elsevier; 2013.
31. Fischer MD, Gustilo RB, Varecka TF. The timing of flap coverage, bone-grafting, and intramedullary nailing in patients who have a fracture of the tibial shaft with extensive soft-tissue injury. *J Bone Joint Surg Am.* 1991;**73**(9):1316–22. [PubMed: [1918113](#)].
32. Semel JD, Trenholme G. *Aeromonas hydrophila* water-associated traumatic wound infections: a review. *J Trauma.* 1990;**30**(3):324–7. [PubMed: [2179571](#)].